Cauda equina syndrome: the state of the evidence in 2019

Munchi S Choksey

MD (Cantab) FRCS (Surgical neurology)

Consultant neurological and spinal surgeon

Spinal neurosurgery

- 35 years of experience
- 6000 + lumbar spinal
- 1200 + neck operations
- Thoracic spines
- Degenerative disease
- Fractures,
- Tumours
- Infections
- Paediatrics
- Busy legal practice

CES - objectives

- Anatomy and physiology
- Pathogenesis – why things go wrong
- Definitions - varied
- Clinical presentation
- Natural history
- Investigation, MRI and its limitations
- Action - current guidelines from BASS and SBNS
- Which operation ?
- Outcomes - expected and actual

Acute CES: genuine problem or “crying wolf”

- Back pain is very common
- Over 7 million “sufferers” in UK at any one time
- Over 100 million working days lost p.a
- Spot the genuine case
- Clinically difficult – but then if it was easy everyone would do it:
- 5 years in medical school – hs to be worth something

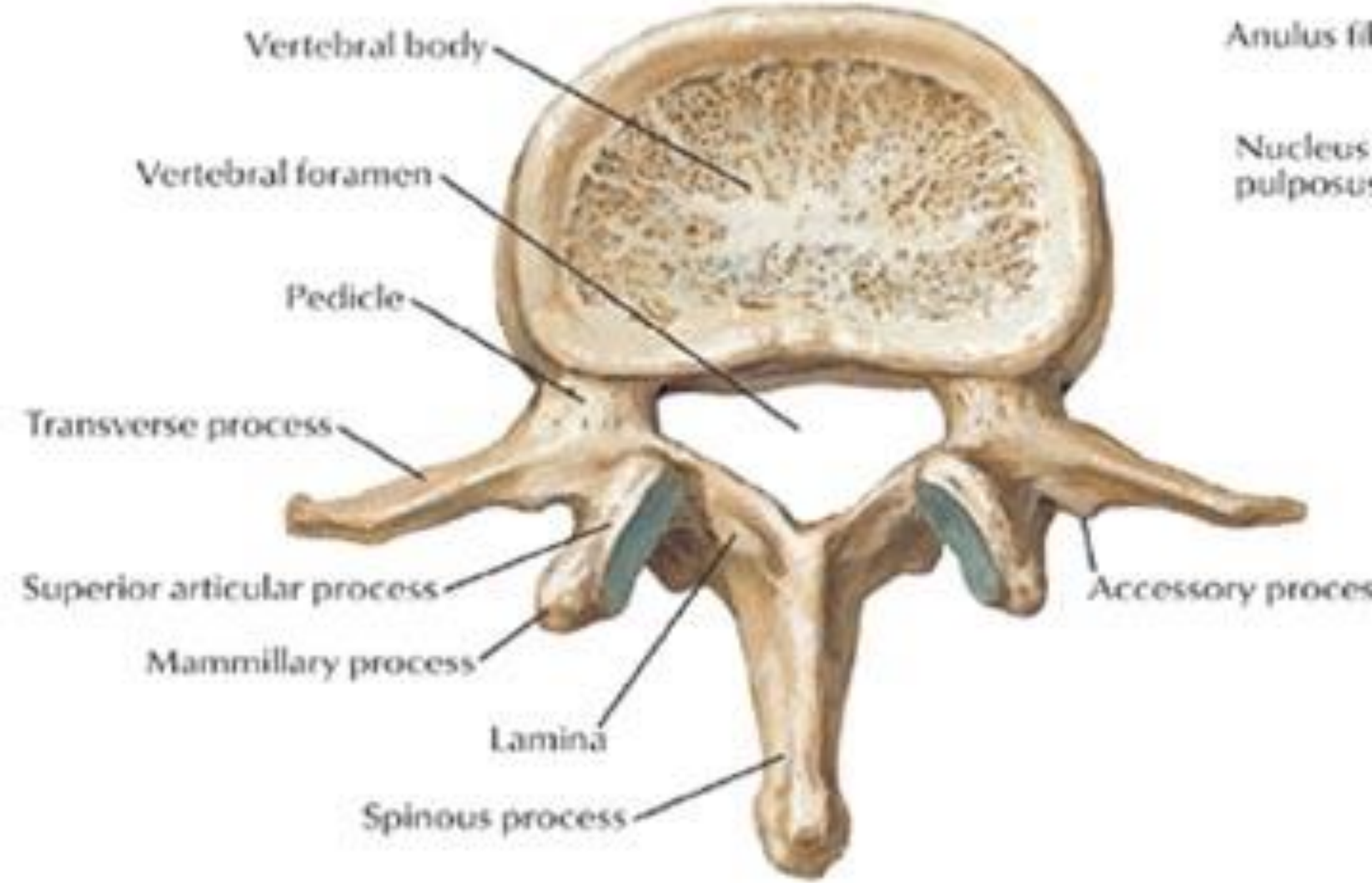

L2 vertebra: superior view

Lumbar spine anatomy

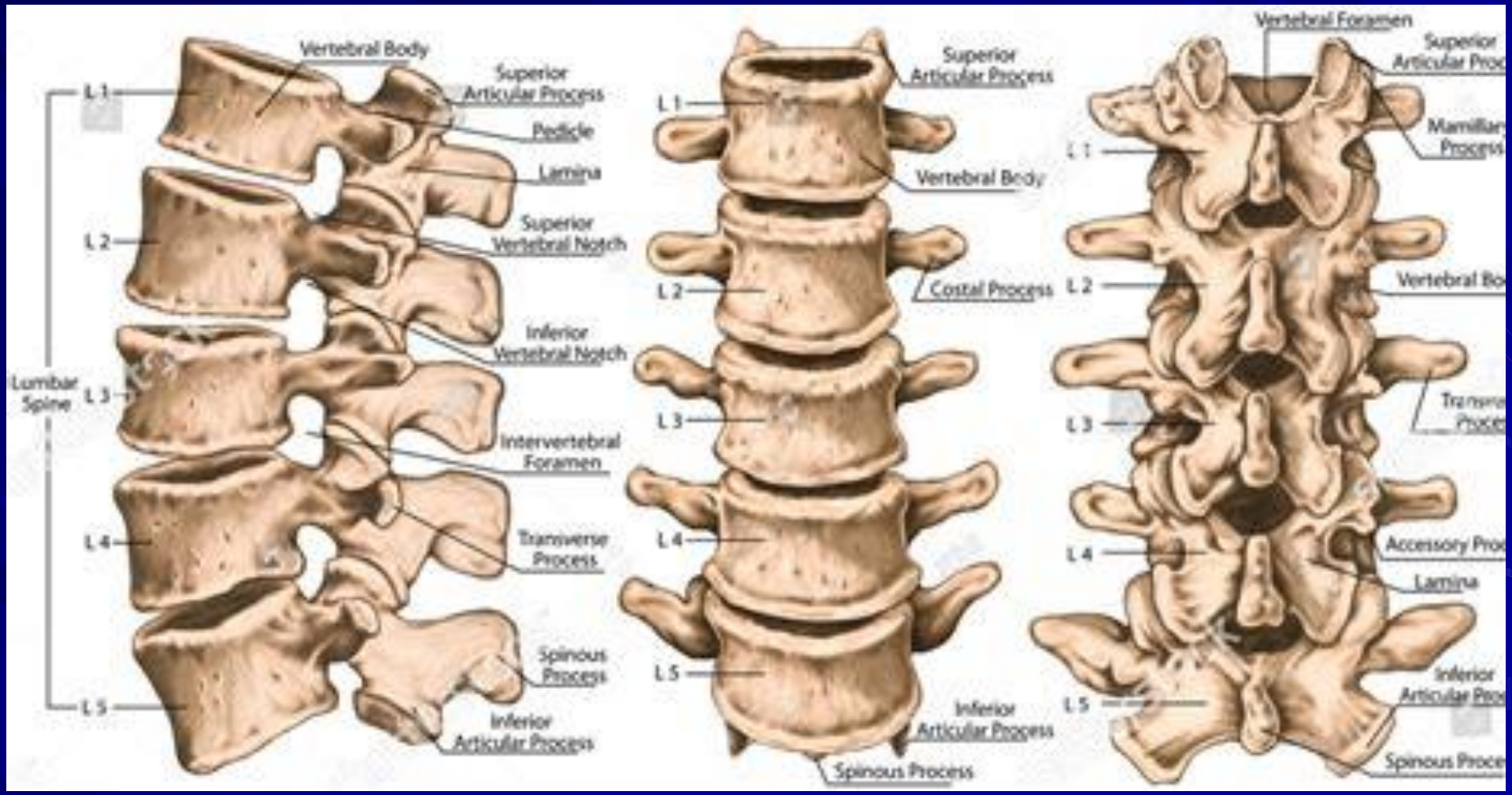

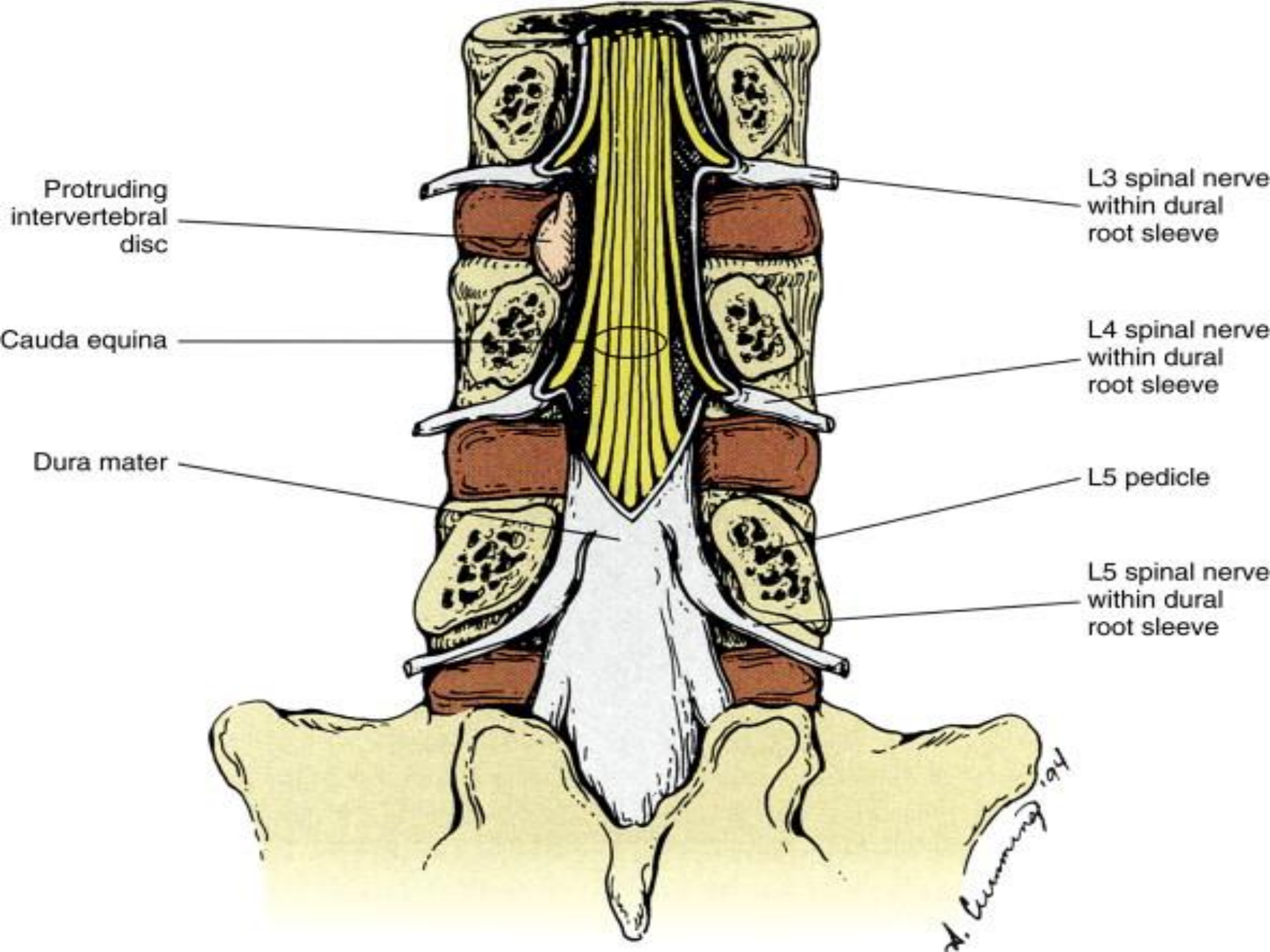
Protruding intervertebral disc
Cauda equina
Dura mater
L3 spinal nerve within dural root sleeve
L4 spinal nerve within dural root sleeve
L5 pedicle
L5 spinal nerve within dural root sleeve

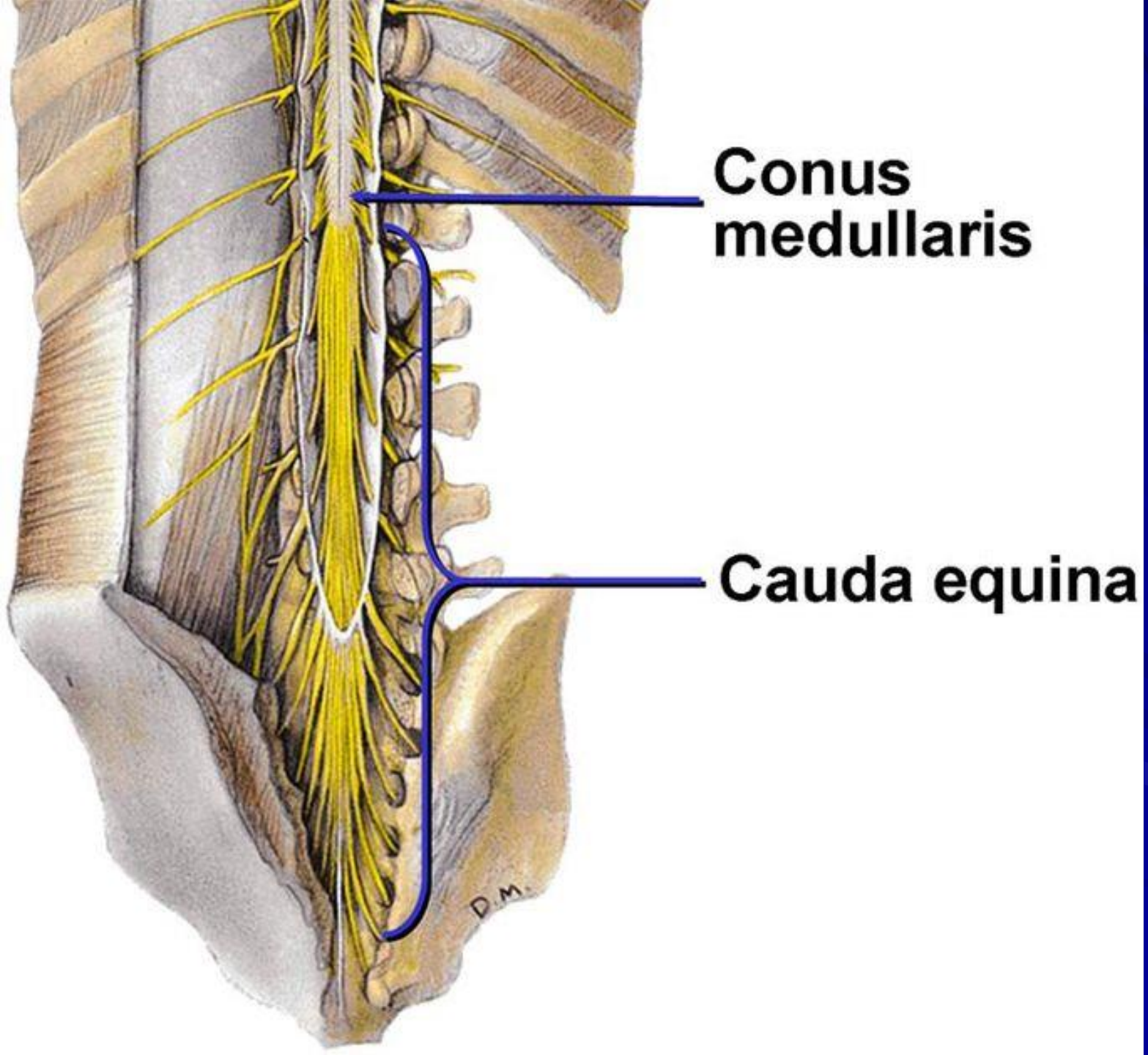
Conus medullaris
Cauda equina
D.M.

Cauda equina blood vessels
Run longitudinally.
No anastomoses across roots
Loss of a segment of blood supply – no recovery

Ischaemia

- **But: death is not the mere stoppage of a machine; it is also total ruin of the supposed machinery. Similarly-and this is a lesson which I wish to emphasize as strongly as I can - partial anoxaemia means not a mere slowing down of life, but progressive and perhaps irreparable damage to living structure.**
- **J S Haldane**
- **A Lecture on the Symptoms, Causes, and Prevention of Anoxaemia (Insufficient Supply of Oxygen to the Tissues), and the Value of Oxygen in its Treatment**
- **Br Med J 1919; 2:65 (Published 19 July 1919)**

Ischaemia stops the machine: then wrecks the machinery

And:

The longer and harder the nervous system is squeezed, the worse the outcome.

Pathophysiology

- Takahashi et al
- Compression not the **sole** cause
- Combination of chemical irritation and compression
- Local high concentration of inflammatory mediators
- Vascular damage, thrombosis and infarction


T

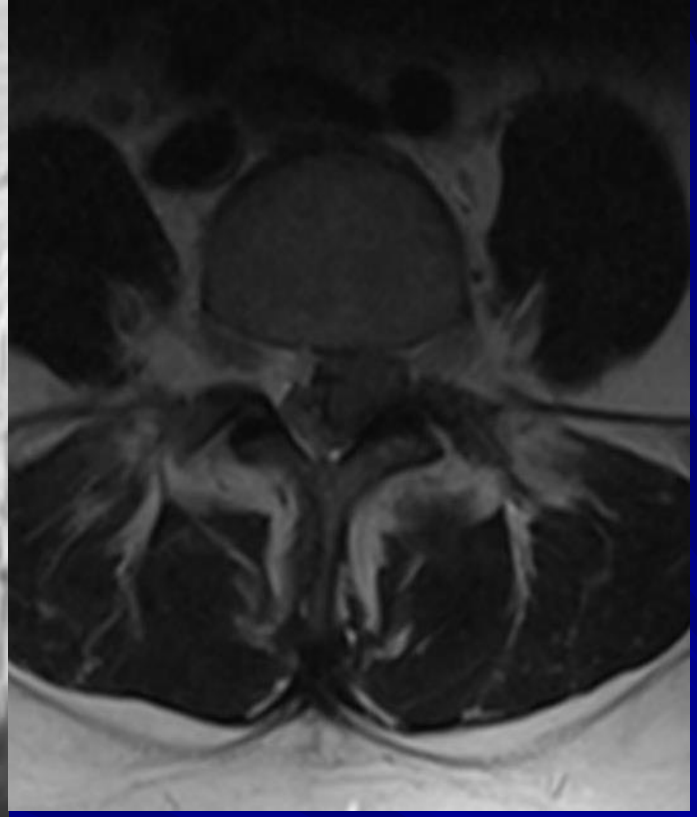

Definitions:

Kostuik, in a review article, defined cauda equina syndrome as a complex of symptoms and signs consisting of low back pain, unilateral or bilateral sciatica, motor weakness of the lower extremities, sensory disturbance in the saddle area, and loss of visceral function

Kostuik JB, Harrington I, Alexander D, Rand W, Evans
D Cauda equina syndrome and lumbar disc herniation.

J Bone Jt Surg 1986;68A:386–91.

CES Definition; all clinical

There is no universally accepted definition of CES

The presence of low back pain,

unilateral or bilateral sciatica

saddle anaesthesia, motor weakness in the legs

loss of sexual function.

reduced sensation of bladder fullness

rectal and urinary incontinence

time of onset of symptoms and/or signs of disturbed urinary, rectal and perineal function

Ahn UM, Ahn NU, Buchowski JM et al.

Cauda equina syndrome secondary to lumbar disc herniation: a meta-analysis of surgical outcomes.

Spine 2000;25:1515-1522

Three classic patterns of presentation have been described.
It can present acutely as the first symptom of lumbar disc herniation (type 1);
as the endpoint of a long history of chronic
back pain with or without sciatica (type 2);
or insidiously in a more chronic way with slow progression
to numbness and urinary symptoms (type 3).

Fairbank et al

Most clinicians
now divide cauda equina syndrome into two
clinical categories

incomplete cauda equina syndrome, in which
there is reduced urinary sensation, loss of desire to
void, or a poor stream, but no established retention or
overflow (CESI)

cauda equina syndrome with
retention, in which there is established urinary retention and overflow (CESR)

Fairbairn et al

3 categories (all clinical)

Suspected or threatened (CESS)

Incomplete (CESI)

Complete (CESR)

Todd (2015)

However there is a consensus that it is a clinical diagnosis.
It is very commonly a PROGRESSIVE disorder

Deterioration may be rapid: even precipitous.

Function lost is unlikely to be regained.

The clock starts ticking at presentation.

All delays are cumulative, and are likely to be harmful

CES presentation

- Early to Late
- Spectrum.
- Sciatica – (bilateral) and a bit of genital numbness……
- Excellent outcomes
- To motor loss, saddle anaesthesia, loss of anal control….
- Poor outcomes

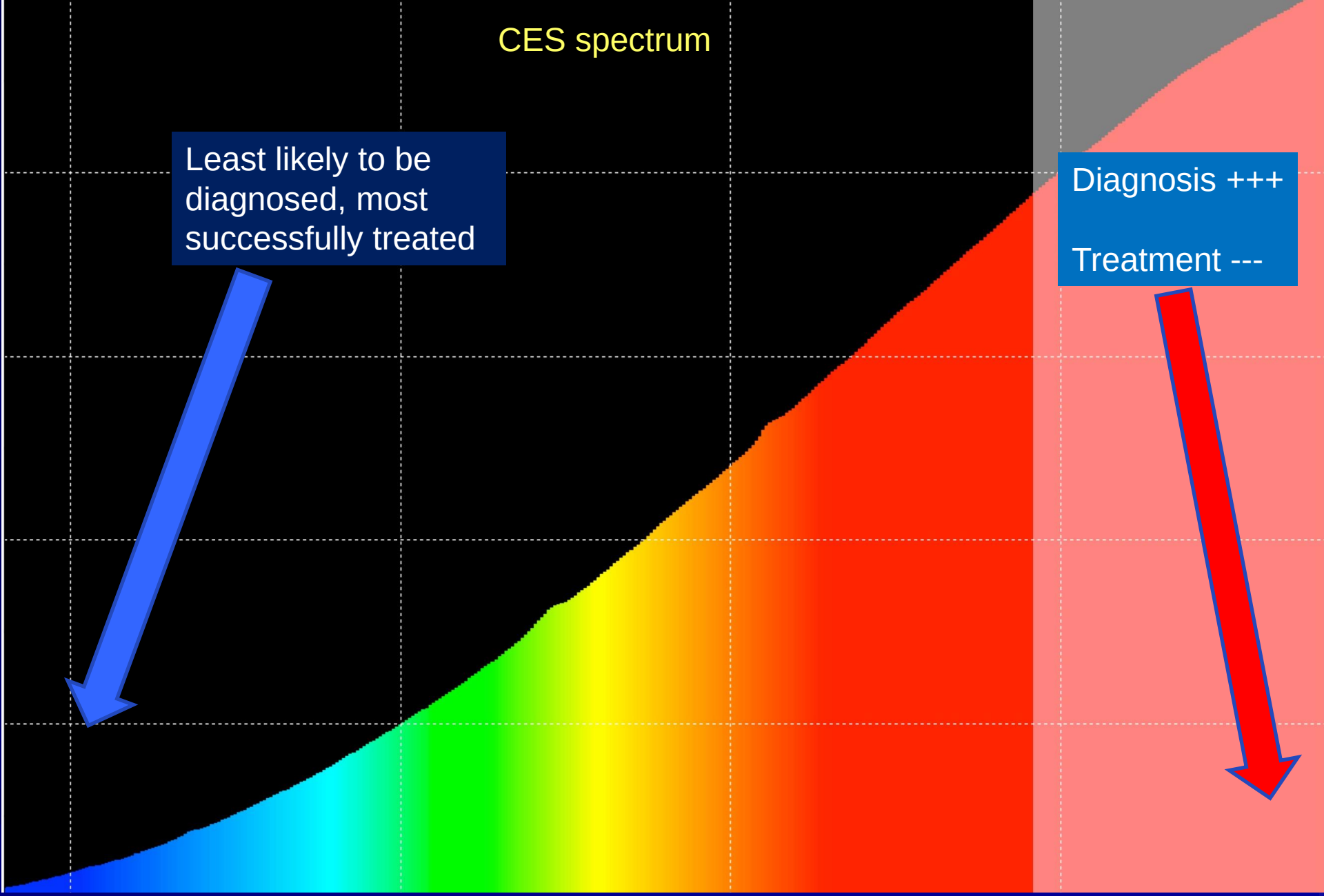

Threatened…..……..Incomplete……Complete

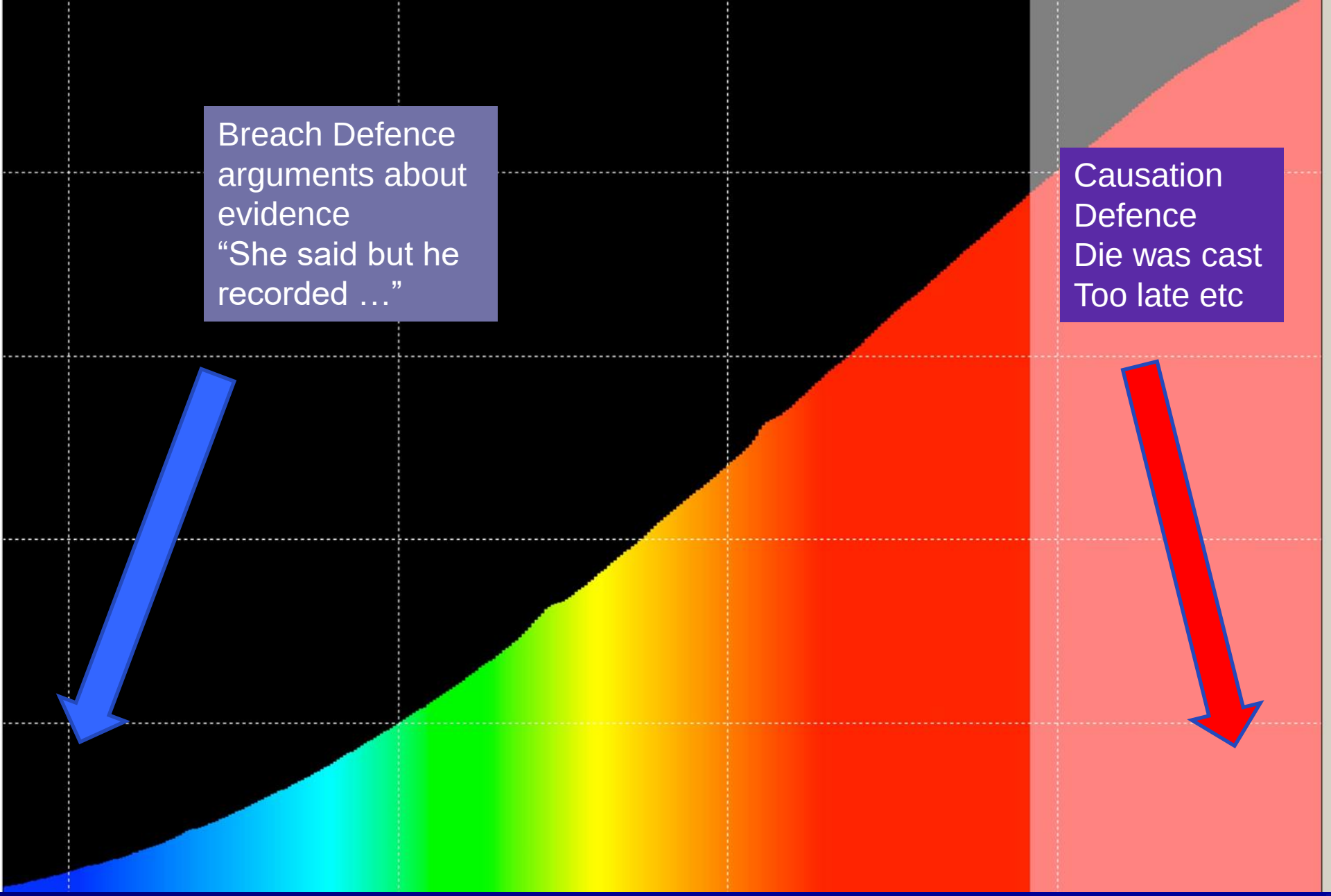

CES Legal arguments

Spinal History

- Red flags – symptoms precede signs
  - Bilateral sciatica
  - Intractable pain
  - Progressive numbness/weakness
  - Saddle/genital anaesthesia
  - Erectile dysfunction
  - Sphincter disturbance – any including wind
  - Any or all may be present, and VARY, especially in the early stages

Discrepancies in the records.

I said ….numbness in “bum” difficulty with wee etc

No GP record

Courts favour the clinical record, not some recall by the patient 2 years later, when there has been the opportunity to re-consider the history etc

Did the GP do a PR? If so, why?

Late feature

Acute spinal pain: CES and infection

- Worrying symptoms

- Pain
  - constant
  - Getting inexorably worse
  - Night pain – waking from sleep (mass)
  - Extreme reluctance to move (infection/ instability)
  - “unwell” patient: gut feeling

Examination

- Red flags - signs
  - Neurological features –Numbness and Weakness
  - Sphincteric / genital involvement
  - Note that loss of anal tone and squeeze is the “last thing to go”
  - Any suggestion of infection or tumour

MYOTOMES

Hip flexion L2 and L3

Hip extension L 4 and L5

Knee Extension L3 and L4

Knee flexion L5 and S1

Ankle dorsiflexion (L4) mainly L5

Ankle Plantar Flexion S1 (poss.S2)

Perianal corrugator cutis ani – S 2 3 4 “wink reflex”

Anal tone and squeeze S 2 3 4

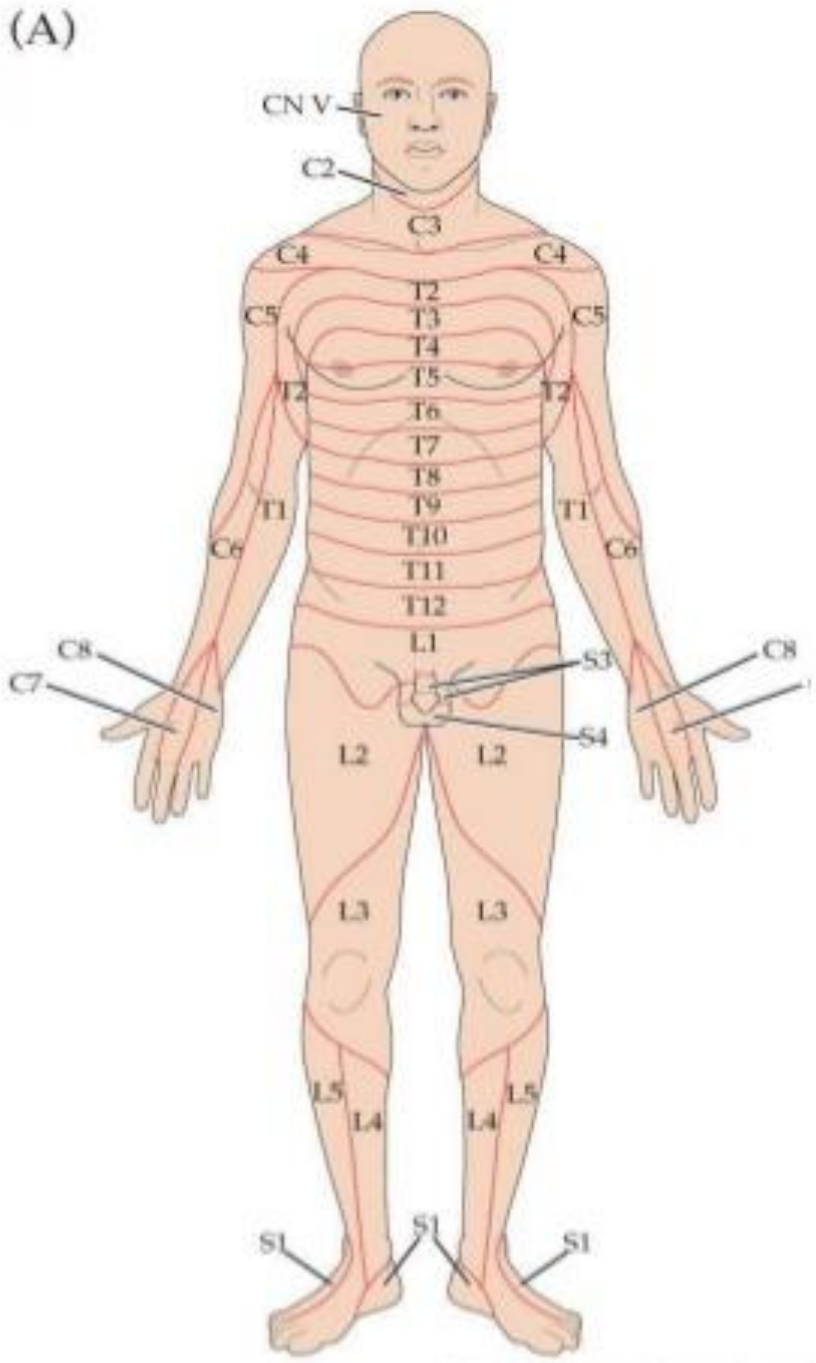

© 2002 Sinauer Associates, I

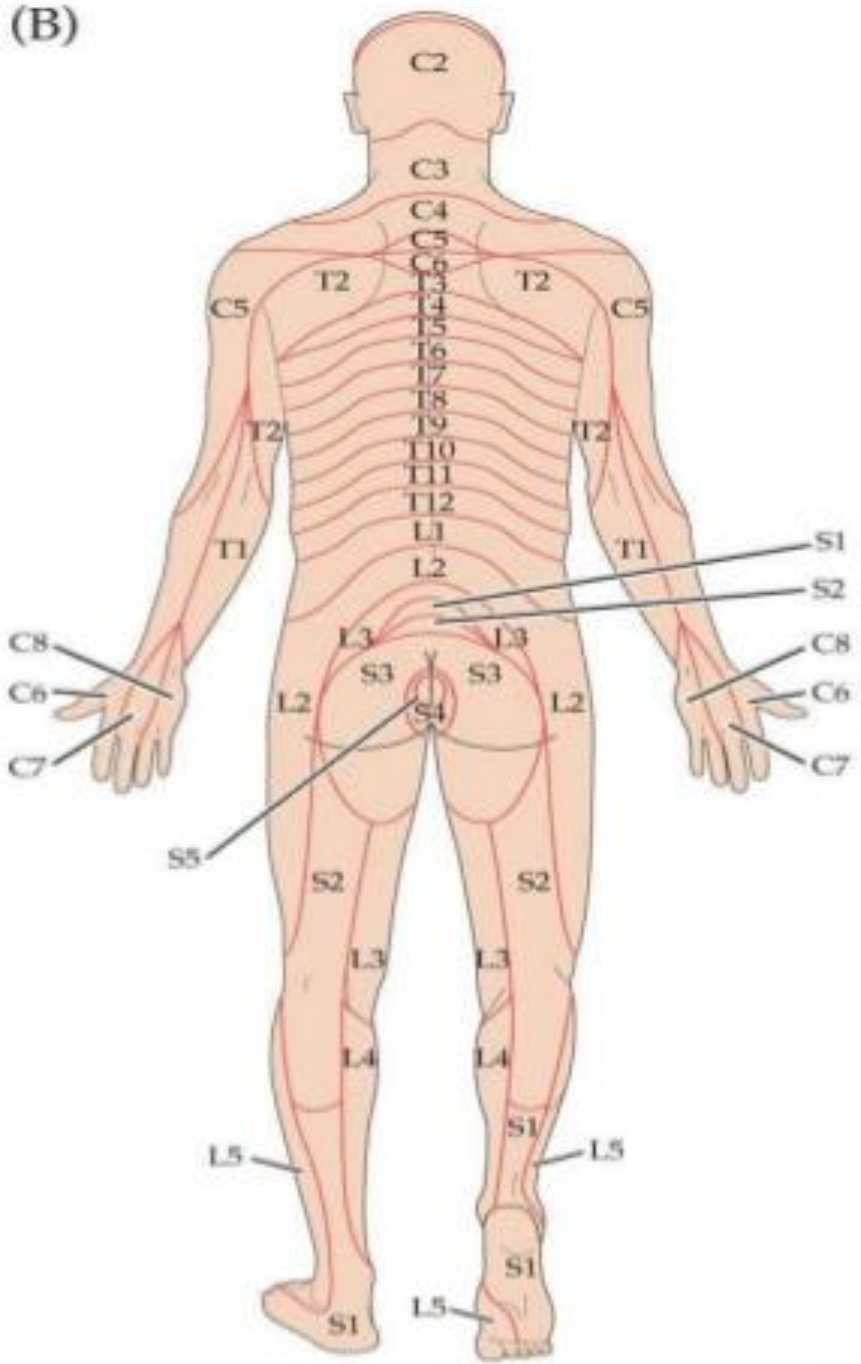

© 2002 Sinauer Associates, Inc.

Acute CES

There is a common misconception that a normal neurological examination excludes an incipient, threatened or partial cauda equina syndrome. it does not. Symptoms alone are sufficient indication to trigger emergency management.

See Fairbairn.. Todd..

Cauda Equina Syndrome

- Avoid the Trap
  - Acute *central* disc herniation at L4-5 or L5-S1
    - The sacral roots lie centrally within the dural sac
    - Sparing of the lumbar, and even S1, roots may be present
      - Total preservation of leg strength possible
      - Bowel and bladder may be completely paralyzed
      - Perineal anesthesia present
    - The sacral roots are very delicate
      - Recovery may not occur, even with relatively expeditious decompression

Cost of scanning

- On the other hand…..
- Incremental cost of MRI is probably in the region of £ 100, Cost of missed cauda equina syndrome – between £500000 and £1000000 plus litigation
- No brainer???
- You would think so

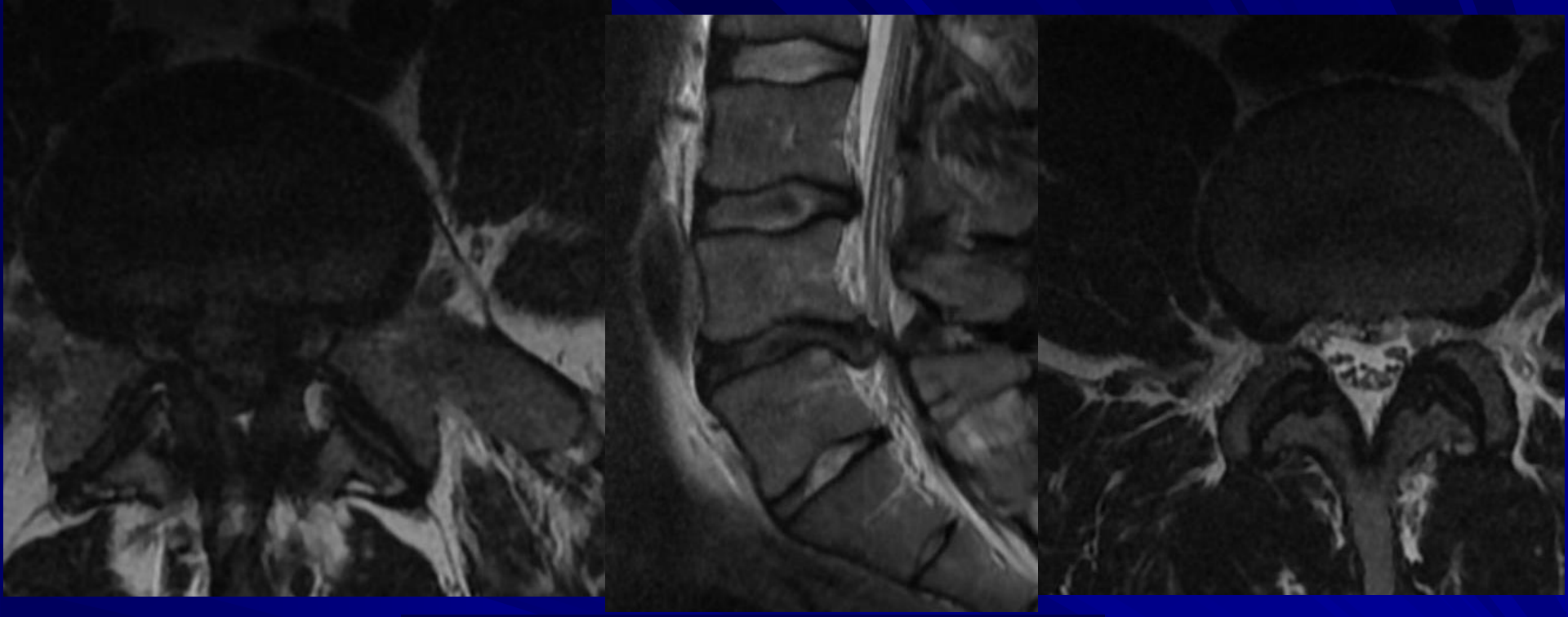

Massive L4/5 disc prolapse.

No CSF visible around cauda equina

Surgery mandatory

However:

It is not necessary for a patient to have a “complete blackout” of the CSF space around the nerve roots for there to be significant cauda equina dysfunction.[7]

Table 3
Level of herniated disc and greatest canal compromise on axial MRI in 33 patients, all judged to have CES by spinal orthopaedic surgeons

Level of herniated disc	Number of patients
L2/3	2
L3/4	1
L4/5	18
L5/S1	12
Greatest canal compromise 0–25%	1
26–50%	3
51–75%	13
76–100%	15

Note that over half had scans where the compromise was less than 75%.

Quereshi and Sell (2007)

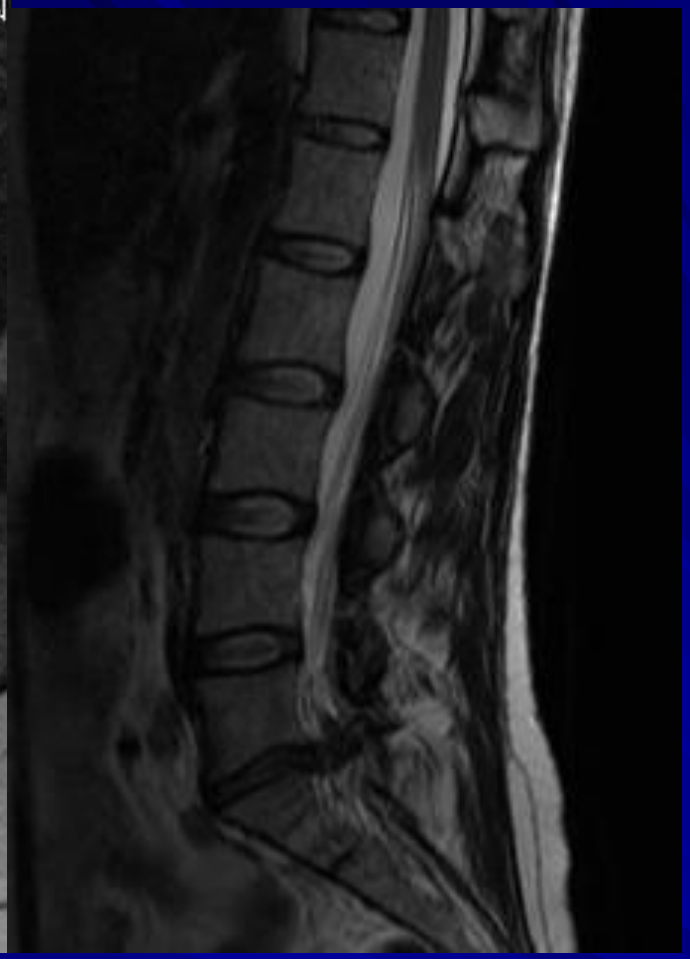

This 36 year old girl had significant cauda equina dysfunction, and residual long-term loss of bladder control and genital sensation. Unilateral nerve compression, if severe, can cause major long term disability. However, the orthopaedic expert kept repeating “but the scan does not show CES” despite agreeing that CES is a clinical diagnosis.

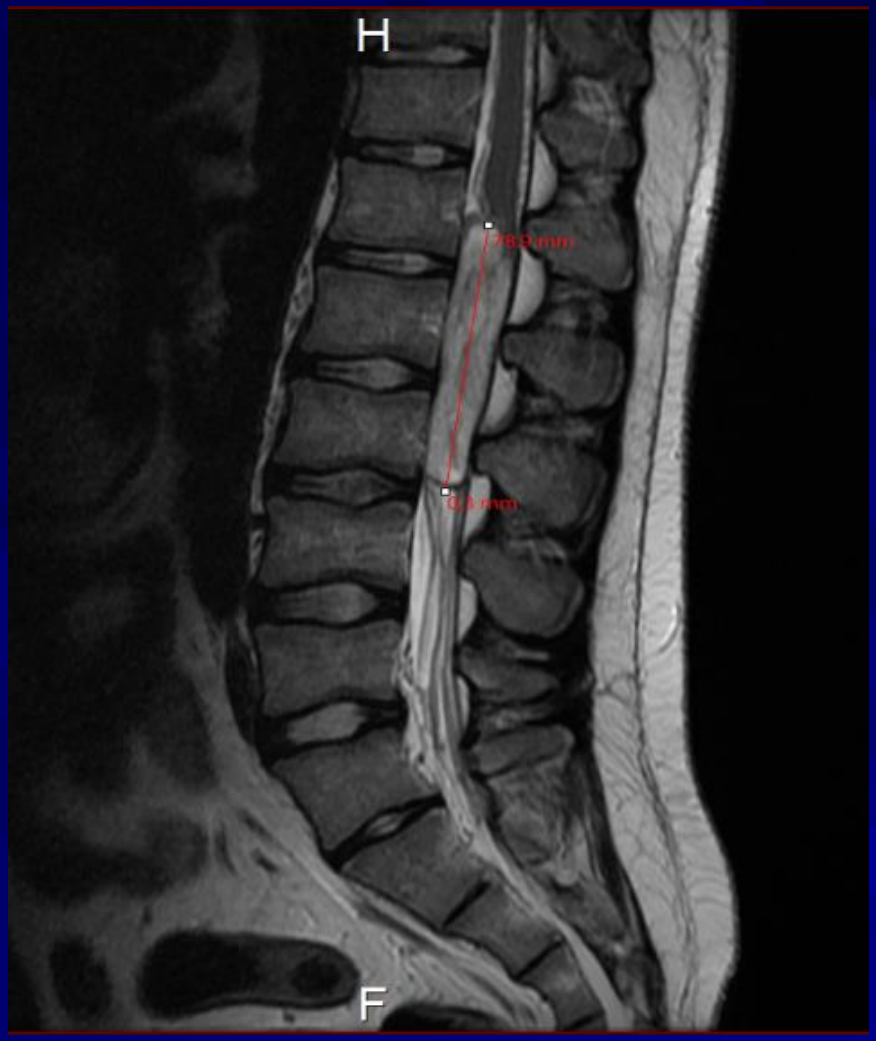

23 year old man with bilateral sciatica – delays and intra-tumoural haemorrhage

Lumbar spinal empyema

From Warwick

Exquisite pain

Virtually paraplegic
Very good recovery
No instability

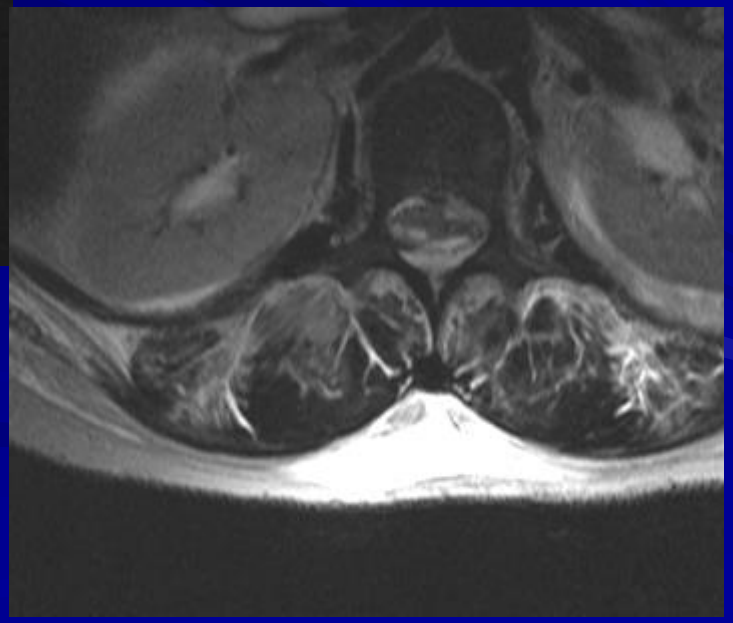

Acute CES

- **Triage scheme**
  - **Spinal pain (SP) alone – GP unless red flag**
  - **SP + Tingling – OPD**
  - **SP + T + N needs scan soon**
  - **SP + T + N +W – take over, urgent scan**
  - **SP + cauda equina features – admit, treat immediately**
  - **Record exactly what you need in the way of scan, theatre and urgency**

Cauda equina syndrome “6 Ss” my guidance to my juniors

- Starve
- Scan
- Steroids - possibly
- Summon a surgeon
- Surgery
- Six hours

- This way YOU keep out of Court
- If no theatre, anaesthetist, ODP ..Management problem
- Cf. recent spinal cord injury case…

Recent paper on timing :

Srikandarajah et al

Outcome with surgery better 24 hrs better than 48 hours.

Standards of Care for Investigation and Management of Cauda Equina Syndrome

- **Background**
- Cauda Equina Syndrome (CES) is a relatively rare but disabling condition which can result in motor and sensory deficits, incontinence of urine and faeces, and loss of sexual function.
- Any patient with a possible diagnosis of threatened /partial/complete CES requires urgent investigation.
- **Presentation**
- A patient presenting with back pain and/or sciatic pain with any disturbance of their bladder or bowel function and/or saddle or genital sensory disturbance or bilateral leg pain should be suspected of having a threatened or actual CES.

- **Imaging**
- The reliability of clinical diagnosis of threatened or actual CES is low and there should be a low threshold for investigation with an emergency MRI scan at the request of the examining clinician and MRI must be available at the referring hospital 24/7.
- The decision to perform an MRI does not require discussion with the local spinal services.
- The MRI must be undertaken as an emergency in the patient's local hospital and a diagnosis achieved prior to any discussion with the spinal services.
- The MRI must take precedence over routine cases and any reasons for a delay or a decision not to perform an emergency scan should be clearly documented.
- If MRI is contraindicated, discussion with local spinal services is appropriate.

- **There are four potential outcomes from the investigation**
- 1. Cauda equina compression confirmed leading to immediate referral to an appropriate surgical service.
- 2. Cauda equina compression excluded but a potential structural explanation of pain identified. This should precipitate appropriate advice about potential future cauda equina symptoms and may include referral via local spinal pathways during working hours.
- 3. Non-compressive pathology may be identified (e.g. demyelination) which should precipitate referral to the appropriate service.
- 4. No explanation of the patient's symptoms may be apparent. An appropriate plan for further management is required and may include a cervico-thoracic MRI and referral to continence services.

NB Outcome 2 is very worrying as CES is a CLINICAL and not a RADIOLOGICAL diagnosis.
This is going to lead to a lot of argument, not least in the Courts.
The guidelines are simply WRONG about this point.

- **Surgery**
- Nothing is to be gained by delaying surgery and should be undertaken at the earliest opportunity, considering the duration and clinical course of symptoms and signs, and the potential for increased morbidity while operating in the night. We do not consider that there is anything in the literature that justifies contravention of this principle and reasons for any delay in surgery should be clearly documented.

Ambiguous? Do we expect surgery at night or not? Why delay at all?

Which operation?

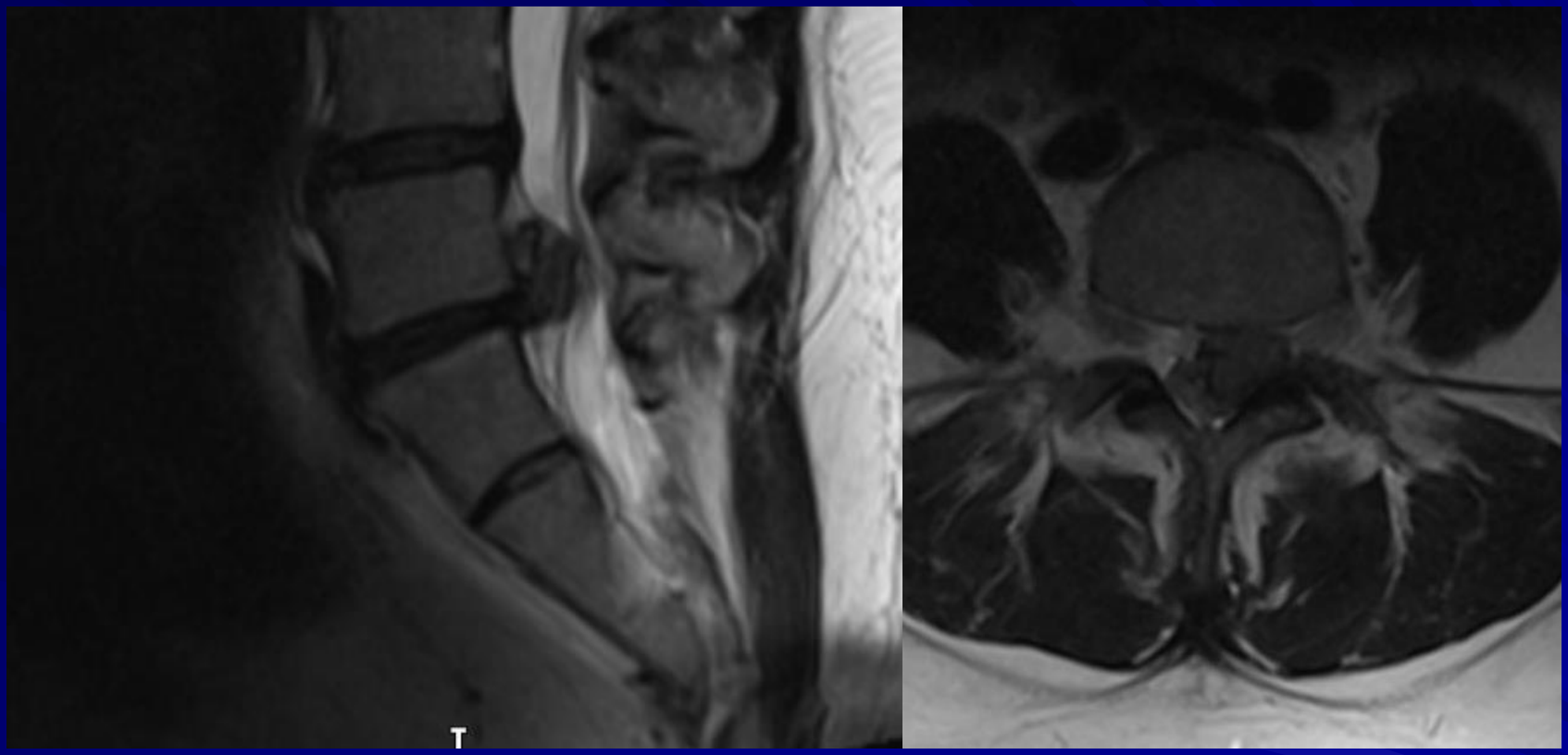

Massive disc prolapse

Full laminectomy: always been my practice

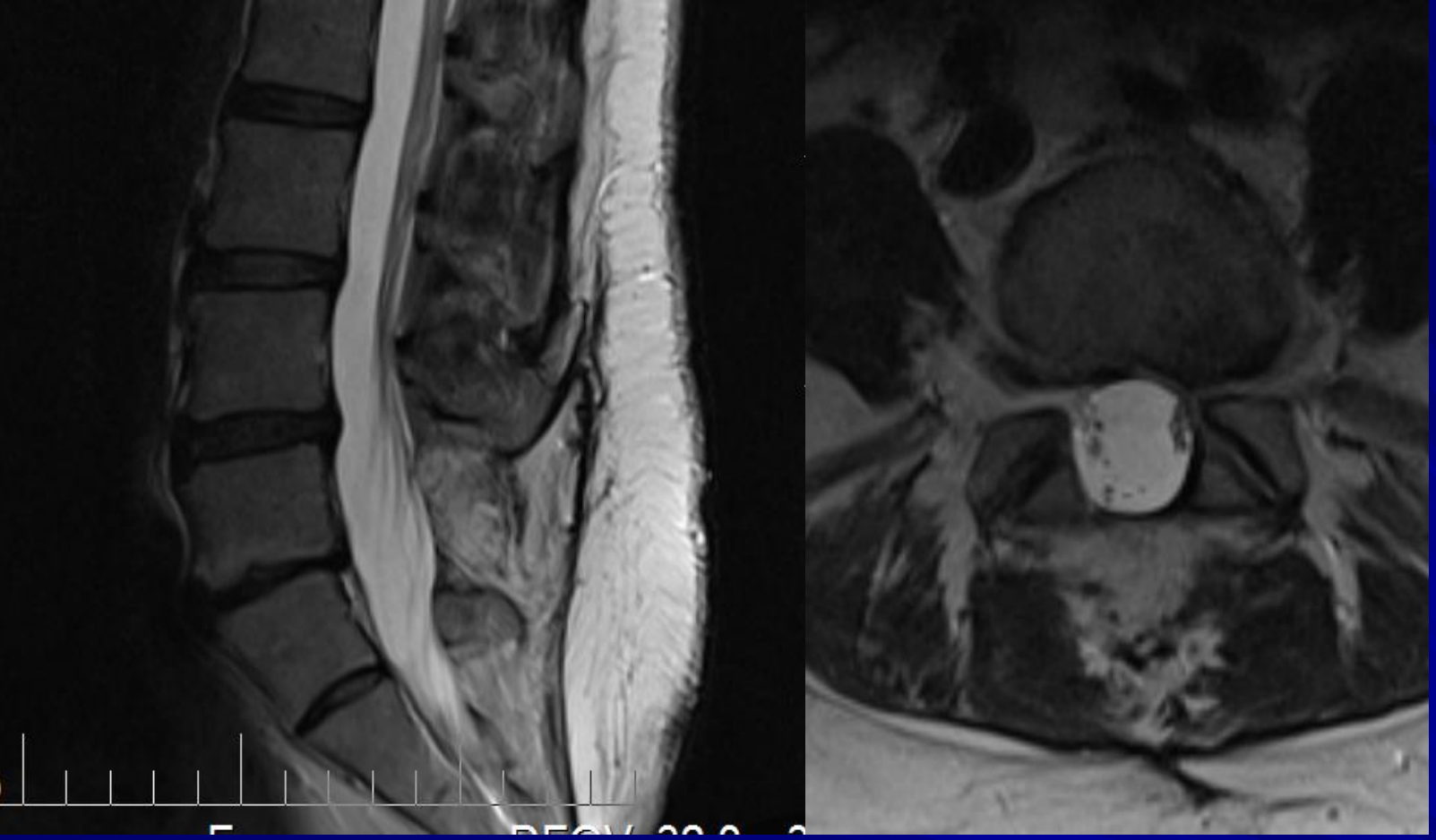

3 years later came back with back pain……..

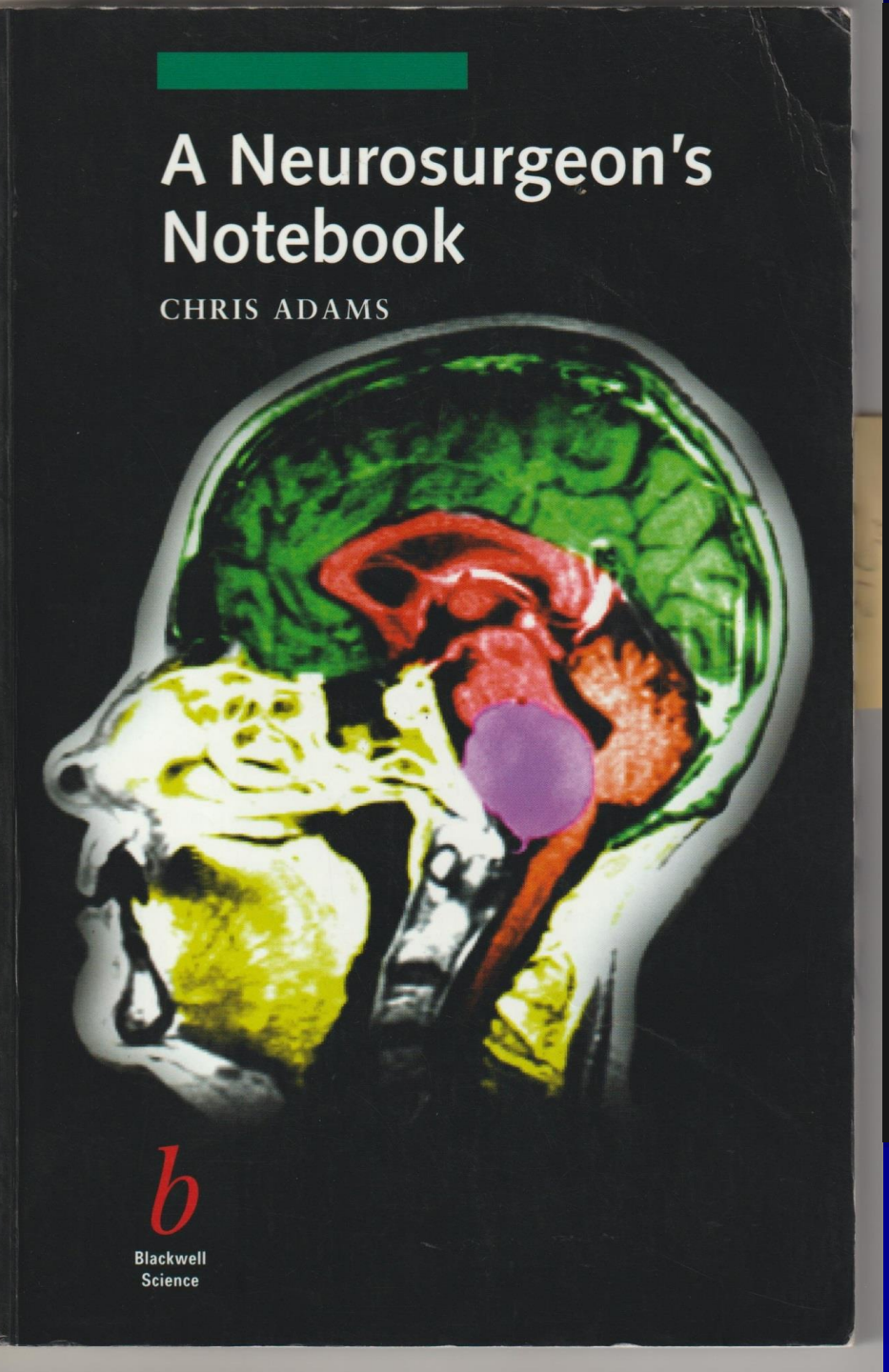

Recommended reading for ALL neurosurgeons in training in the UK

One of the foremost neurosurgeons of his generation

Full of wisdom

Tells you about his mistakes……..

From Adams: A neurosurgeons Notebook

I prefer a decent exposure when carrying out lumbar disc surgery for two reasons. First, it reduces the risk of missing a disc fragment and allows a more complete removal of disc material, but perhaps of more importance, it allows a good decompression of the nerve root, which allows safer retraction as well as better post-operative relief of pain. I never mind removing the medial half of a facet joint on one side to obtain adequate decompression and please do not remove a central disc prolapse through a fenestration. I have seen too many patients develop a post-operative cauda equina syndrome because of an inadequate bony decompression. I always carry out a full laminectomy in these circumstances.

"There is no place in the management of this condition for the micro discectomy approach that is routine for the radicular pain syndrome as sciatica due to disc herniation. The traditional mid line approach with bilateral exposure of laminae and complete laminectomy should be performed to immediately decompress the cauda equina prior to manipulation the thecal sac in an attempt to remove the disc fragments."(H Bridwell et al., 1997 page 1558)

There is a modern tendency to disregard these warnings, and to carry out surgery through a small exposure. This is a very poor approach – and in my view negligent: particularly if there is a dural tear.

Outcome.

This is a devastating condition.
Neuropathic pain more likely – lecture in itself
Dreadful effect from impotence; anhedonia/loss of all sexual function
Incontinence of urine, flatus and faeces
Employment difficult/ impossible

Degree of recovery at 2 years determined by:

Deficit at the time of surgery: what goes into theatre should come out of theatre

Evidence of subsequent recovery.

Material vs absolute contribution to poor result.

Cauda equina syndrome feeds a considerable gravy train.
This sign was in Leeds….

Question Time?

CES summary

- Simple anatomical and pathophysiological principles
- Clinical diagnosis H and E
- Imaging NOT the be and end all:
- Neurosurgical emergency
- Decompression must be expeditious and WIDE
- Time is of the essence
- Best results in CESS; then CESI; then CESR